Special REPORT

Understanding Updates to IPF/PPF Practice Guidelines:

A Multidisciplinary Roundtable Discussion

Discussion Moderator

Lida Hariri, MD, PhD
Associate Professor of Pathology
Massachusetts General Hospital
Harvard Medical School
Boston, Massachusetts

Faculty

Ann Chauffe, DO, MPH
Assistant Professor of Medicine
Division of Rheumatology and Clinical Immunology
University of Florida College of Medicine
Gainesville, Florida

Lisa Kopas, MD
Assistant Professor of Pulmonary Medicine
Pulmonary Critical Care and Sleep Medicine
Weill Cornell Medical College
Houston Methodist Hospital
Houston, Texas

Shawn D. Teague, MD
Associate Professor of Radiology
National Jewish Health/University of Colorado
Denver, Colorado

Introduction

Interstitial lung disease (ILD) encompasses a diverse group of more than 200 disorders that are characterized by varying degrees of lung inflammation and fibrosis.[1] ILD symptomology can cause severe physical impairment that can negatively affect patient quality of life and the ability to perform activities of daily living.[2,3] Many known factors can lead to the development of ILDs, including genetics, age, medical conditions including autoimmune disorders, and environmental exposures.[1] For many patients, however, the cause of ILD remains unknown.[1]

Idiopathic Pulmonary Fibrosis

Idiopathic pulmonary fibrosis (IPF) is a chronic, progressive, fibrosing ILD with poorly understood etiology and a poor prognosis.[4] In the United States, per 10,000 people, the mean unadjusted incidence of IPF is 0.64 and the mean prevalence is 1.37.[5] Historical studies have shown that for women, incidence per 100,000/year is estimated at 7.4 and 10.7 for men; prevalence is estimated at 13.2 for women and 20.2 for men per 100,000, with rates for both increasing with age.[6] IPF places a significant burden on patients, affecting nearly every domain of health-related quality-of-life surveys, with the greatest effects in detriments to physical functioning, disease symptoms, and hindrance to patient independence.[7] The clinical course of IPF remains largely unknown due to its variable and unpredictable natural history.[4,8] Some patients experience a slower disease course with relatively minor changes over time; other patients progress quickly and follow a rapid decline, with acute exacerbations quickly altering the disease course.[8] It remains difficult to predict how IPF will progress for an individual patient, but prognosis for IPF is generally poor.[4] Median survival ranges

McMAHON PUBLISHING

Boehringer Ingelheim

This special report was supported by Boehringer Ingelheim Pharmaceuticals, Inc.

from 2.5 to 3.5 years after IPF diagnosis,[9] and 3- and 5-year survival rates are 62% and 46%, respectively.[10] Several risk factors for IPF are known: The disease occurs most often in older adults and men, and IPF development can be influenced by genetics, the lung microbiome, comorbidities, and extrinsic factors including smoking and environmental exposures.[11]

Development of IPF/PPF Guidelines

IPF can be challenging to diagnose[12]; an IPF diagnosis is a diagnosis of exclusion with a variety of clinical presentations that can range in severity and require consideration of multiple complex clinical, pathologic, and radiological features.[13,14] Similarities in symptoms and presentation between IPF and other ILDs and/or inflammatory conditions contribute to IPF diagnosis often being delayed, which can negatively affect survival.[15] In patients without IPF, other forms of progressive pulmonary fibrosis (PPF) have a similarly varied and complicated diagnostic umbrella that encompasses multiple progressive fibrotic diseases.[16] The American Thoracic Society (ATS), European Respiratory Society (ERS), Japanese Respiratory Society (JRS), and Asociación Latinoamericana de Tórax (ALAT) provide clinical recommendations for the diagnosis and management of IPF, and have updated their guideline to include PPF.[16] The guideline for IPF diagnosis and management was published in 2011 and updated in 2015 and 2018.[17-19] The 2022 guideline updates diagnostic criteria for IPF and defines/provides diagnostic criteria for PPF. By including PPF, the guideline addresses progress in non-IPF ILDs.[16]

Due to the challenging nature of these conditions, clinical guidelines recommend a multidisciplinary approach to treatment and management by clinicians who specialize in ILDs.[19] On September 13, 2022, in Kansas City, Missouri, a multidisciplinary panel of clinicians who are noted for their expertise in IPF/PPF discussed the recent guideline changes for diagnosing and managing IPF and identifying PPF. Moderated by Lida Hariri, MD, PhD, an associate professor of pathology at Massachusetts General Hospital/Harvard Medical School, in Boston, Massachusetts, panel experts explained the recent guideline changes and shared their approaches and perspectives on the diagnosis and management of patients with IPF and PPF. This Special Report reviews the guideline updates and provides practical considerations for ensuring optimal, guideline-concordant diagnosis and support for patients with IPF and PPF.

Updates to the ATS/ERS/JRS/ALAT Clinical Practice Guideline

In 2022, key updates were made to the ATS/ERS/JRS/ALAT clinical practice guideline for IPF, refining the definitions and diagnostic features of IPF for radiologists and pathologists.[16] The panelists discussed these updates and their clinical implications, highlighting impactful changes and identifying areas with remaining unmet needs. The panelists agreed that one of the most notable evolutions of the guideline over time has been the increasing reliance on imaging before biopsy retrieval.[16] Lisa Kopas, MD, an assistant professor of pulmonary medicine and pulmonary critical care and sleep medicine at Weill Cornell Medical College/Houston Methodist Hospital, in Houston, Texas, explained that throughout the history of the guideline documents, imaging has become more important as a preliminary step in a patient's workup. "The focus on not jumping to surgical biopsy has been a benefit for the patients," Dr Kopas said. "Leaving more invasive biopsy options for the indeterminate cases, knowing that if there is an alternative diagnosis, we go down that route."

Radiology

Usual interstitial pneumonia (UIP) is a hallmark of IPF and diagnosed radiologically via high-resolution computed tomography (HRCT; Figure 1).[16,20] In the 2018 guideline, patterns of certain features found on HRCT, including honeycombing, traction bronchiolectasis, traction bronchiectasis, ground-glass opacification, and/or reticulation, among others, were divided into 4 categories to aid UIP diagnosis.[19] These 4 categories each have their own associated probability of UIP diagnosis: UIP pattern, probable UIP pattern, indeterminate for UIP pattern, and alternative diagnosis.[19] In 2022, these 4 categories were further refined and updated (Table 1).[16] Shawn D. Teague, MD, an associate professor of radiology at National Jewish Health/University of Colorado, in Denver, Colorado, noted that the addition of the 4 categories was a major change in 2018. "Previous to that, there were categories, but the guideline update much better defined the categories," Dr Teague said.

Panelists agreed that the diagnostic categories have been helpful for guiding diagnosis in patients with UIP, and having the alternative diagnosis category ensures coverage of all possible clinical scenarios. Dr Teague explained that "the categories work most of the time. When you see enough patients, there are certain patterns that maybe don't fit directly into one of those 4 categories. With more experience, you begin to recognize some of these more unique patterns. In that situation, you select the alternate diagnosis category and then suggest what you believe is the best underlying diagnosis."

Guideline Recommendations for UIP Diagnosis

According to the guideline, a diagnosis of UIP can be made confidently (>90%) if the following features are present: honeycombing with or without peripheral traction bronchiectasis or bronchiolectasis; heterogeneous, subpleural distribution with basal predominance with or without ground-glass opacification and often with a superimposed reticular pattern (occasionally diffuse, may be asymmetric); presence of irregular thickening or interlobular septa; and possible pulmonary ossification.[16,19] A diagnosis of probable UIP is appropriate for patients with subpleural, basal-predominant reticular abnormalities with peripheral traction bronchiectasis or bronchiolectasis, which may occur with or without ground-glass opacification.[19] Of note, honeycombing is not present in a probable UIP diagnosis.[16,19] The panelists noted that sensitivities are high for diagnoses of definite and probable UIP. Indeed, the positive predictive value of a radiological diagnosis of definite UIP is above 90% for a pathologic diagnosis of UIP.[21,22]

Specifically addressing key radiological features, the 2022 guideline update focuses on identifying honeycombing because of its utility in diagnosing lung fibrosis and correlation with histology.[16] Dr Teague explained that the identification of honeycombing is changing. "We previously described honeycombing as being 3 stacked rows of cysts, but we have progressed to the point now, where even if it is just a single layer, we can call it honeycombing." Dr Teague also noted that it can be challenging to identify honeycombing confidently, particularly in the upper lungs, where it can be confused with paraseptal emphysema.

For indeterminant UIP, patients are diagnosed if HRCT shows fibrotic features but does not meet the criteria for UIP or probable UIP, and an alternative diagnosis is not "explicitly" suggested,

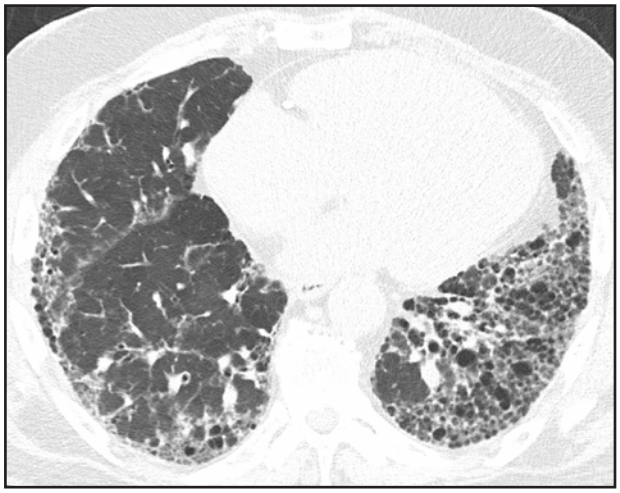

Figure A: A 67-year-old man with typical HRCT imaging appearance of a UIP pattern in a peripheral and basilar predominant distribution.

Notice the reticular abnormality, traction bronchiectasis/bronchiolectasis, and honeycombing. In the absence of an underlying cause, this presentation is consistent with IPF.

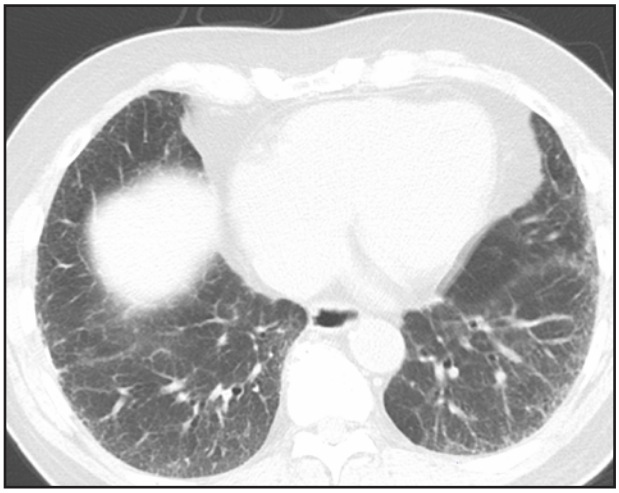

Figure B: A 74-year-old man with the same peripheral and basilar predominant distribution of disease as in Figure A; however, there is only reticular abnormality and traction bronchiolectasis without honeycombing, making this presentation a probable UIP pattern.

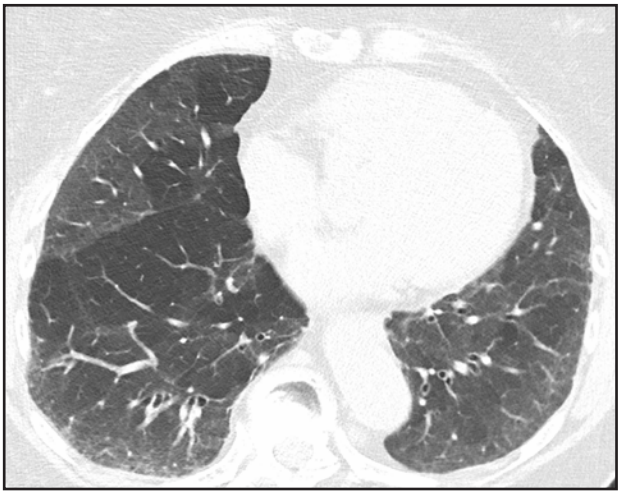

Figure C: An 82-year-old woman with basilar predominant relatively diffuse ground-glass opacity and mild peripheral reticular abnormality.

Also, notice the hyperlucent area of air trapping in the right lower lobe. This pattern would be indeterminant for UIP given the extent of ground glass and the non-specific pattern of air trapping.

Figure D: A 56-year-old woman with basilar predominant reticular abnormality and traction bronchiectasis.

The distribution was very concentrated along the hemidiaphragms bilaterally. There is mild subpleural sparing and the lack of honeycombing. This pattern is consistent with an alternative diagnosis—in this case NSIP related to scleroderma.

Figure 1. Axial images in lung window from 4 patients demonstrating the 4 categories of HRCT imaging for UIP.

HRCT, high-resolution computed tomography; **IPF,** idiopathic pulmonary fibrosis; **NSIP,** nonspecific interstitial pneumonia; **UIP,** usual interstitial pneumonia.

Images courtesy of Shawn D. Teague, MD.

Table 1. HRCT Patterns in IPF

	HRCT pattern			
	UIP pattern	**Probable UIP pattern**	**Indeterminate for UIP**	**CT findings suggestive of an alternative diagnosis**
Level of confidence for UIP histology	Confident (>90%)	Provisional high confidence (70-89%)	Provisional low confidence (51-69%)	Low to very low confidence (≤50%)
Distribution	Subpleural and basal predominant Often heterogeneous (areas of normal lung interspersed with fibrosis) Occasionally diffuse May be asymmetric	Subpleural and basal predominant Often heterogeneous (areas of normal lung interspersed with reticulation and traction bronchiectasis/ bronchiolectasis)	Diffuse distribution without subpleural predominance	Peribronchovascular predominant with subpleural sparing (consider NSIP) Perilymphatic distribution (consider sarcoidosis) Upper or mid lung (consider fibrotic HP, CTD-ILD, and sarcoidosis) Subpleural sparing (consider NSIP or smoking-related IP)
CT features	Honeycombing with or without traction bronchiectasis/ bronchiolectasis Presence of irregular thickening of interlobular septa Usually superimposed with a reticular pattern, mild GGO May have pulmonary ossification	Reticular pattern with traction bronchiectasis/ bronchiolectasis May have mild GGO Absence of subpleural sparing	CT features of lung fibrosis that do not suggest any specific etiology	Lung findings Cysts (consider LAM, PLCH, LIP, and DIP) Mosaic attenuation or three-density sign (consider HP) Predominant GGO (consider HP, smoking-related disease, drug toxicity, and acute exacerbation of fibrosis) Profuse centrilobular micronodules (consider HP or smoking-related disease) Nodules (consider sarcoidosis) Consolidation (consider organizing pneumonia, etc.) Mediastinal findings Pleural plaques (consider asbestosis) Dilated esophagus (consider CTD)

The previous term, "early UIP pattern," has been eliminated to avoid confusion with "interstitial lung abnormalities" described in the text. The term "indeterminate for UIP" has been retained for situations in which the HRCT features do not meet UIP or probable UIP criteria and do not explicitly suggest an alternative diagnosis. Adapted from Raghu G, Remy-Jardin M, Myers JL, et al. Diagnosis of idiopathic pulmonary fibrosis. An official ATS/ERS/JRS/ALAT clinical practice guideline. *Am J Respir Crit Care Med*. 2018;198(5):e44-e68.

CT, computed tomography; **CTD,** connective tissue disease; **DIP,** desquamative interstitial pneumonia; **GGO,** ground-glass opacity; **HP,** hypersensitivity pneumonitis; **HRCT,** high-resolution computed tomography; **ILD,** interstitial lung disease; **IP,** interstitial pneumonia; **IPF,** idiopathic pulmonary fibrosis; **LAM,** lymphangioleiomyomatosis; **LIP,** lymphoid interstitial pneumonia; **NSIP,** nonspecific interstitial pneumonia; **PLCH,** pulmonary Langerhans cell histiocytosis; **UIP,** usual interstitial pneumonia.

Reprinted with permission of the American Thoracic Society. Copyright © 2023 American Thoracic Society. All rights reserved.

Raghu G, Remy-Jardin M, Richeldi L, et al. Idiopathic pulmonary fibrosis (an update) and progressive pulmonary fibrosis in adults: an official ATS/ERS/JRS/ALAT clinical practice guideline. *Am J Respir Crit Care Med*. 2022;205(9):e18-e47.

The *American Journal of Respiratory and Critical Care Medicine* is an official journal of the American Thoracic Society.

according to the 2018 guideline.[19] Up to 30% of patients who are ultimately diagnosed with UIP/IPF may have atypical, inconsistent HRCT features.[23] During the update review process, the guideline committee considered merging the UIP and probable UIP categories, but elected to maintain their separation.[16] Panelists were divided over whether it would be helpful to further subcategorize the potential UIP diagnoses.

Alternative Diagnosis

In some cases, HRCT of a patient under evaluation for IPF may reveal imaging features indicative of an underlying diagnosis. These patients fall into the alternative diagnosis category and can be treated for their specific condition that is resulting in the lung changes.[19] The guideline provides additional information for alternative diagnoses that may be found including bronchocentric fibrosis in the upper lobes or profuse mosaic attenuation that suggests hypersensitivity pneumonitis, posterior fibrotic retraction of the hila in sarcoidosis, or extensive ground-glass opacification with subpleural sparing in fibrotic nonspecific interstitial pneumonia (NSIP).[19] Of note, approximately 20% of patients categorized with an alternative diagnosis following HRCT ultimately are diagnosed with UIP/IPF.[24]

The group of clinicians agreed that there should be more education and research around distinguishing alternative diagnoses. "I don't want to have 10 different categories that I have to memorize, so I think it's more about education regarding the specific alternate diagnosis that you can potentially make from imaging," Dr Teague said. Dr Hariri added, "Some of the gap, right now, is the lack of data. There are certain categories of diseases that HRCTs are fantastic at diagnosing, UIP being one of them. But then there are other diseases where there is not any data to assess the sensitivity and specificity of HRCT for diagnosis—NSIP, for example." The panelists noted that they see an opportunity for artificial intelligence tools to be applied to assist with diagnoses, but acknowledge that it can be difficult to gather data for research as biopsy collection decreases and "ground truth" information is harder to obtain.

Pathology

The 2022 update also reviewed and confirmed guidance for histopathologic features of UIP (common histopathologic features shown in Figure 2).[16,25] According to the guideline, the histologic basis for a UIP diagnosis includes patchy dense fibrosis with architectural distortion (particularly honeycombing),

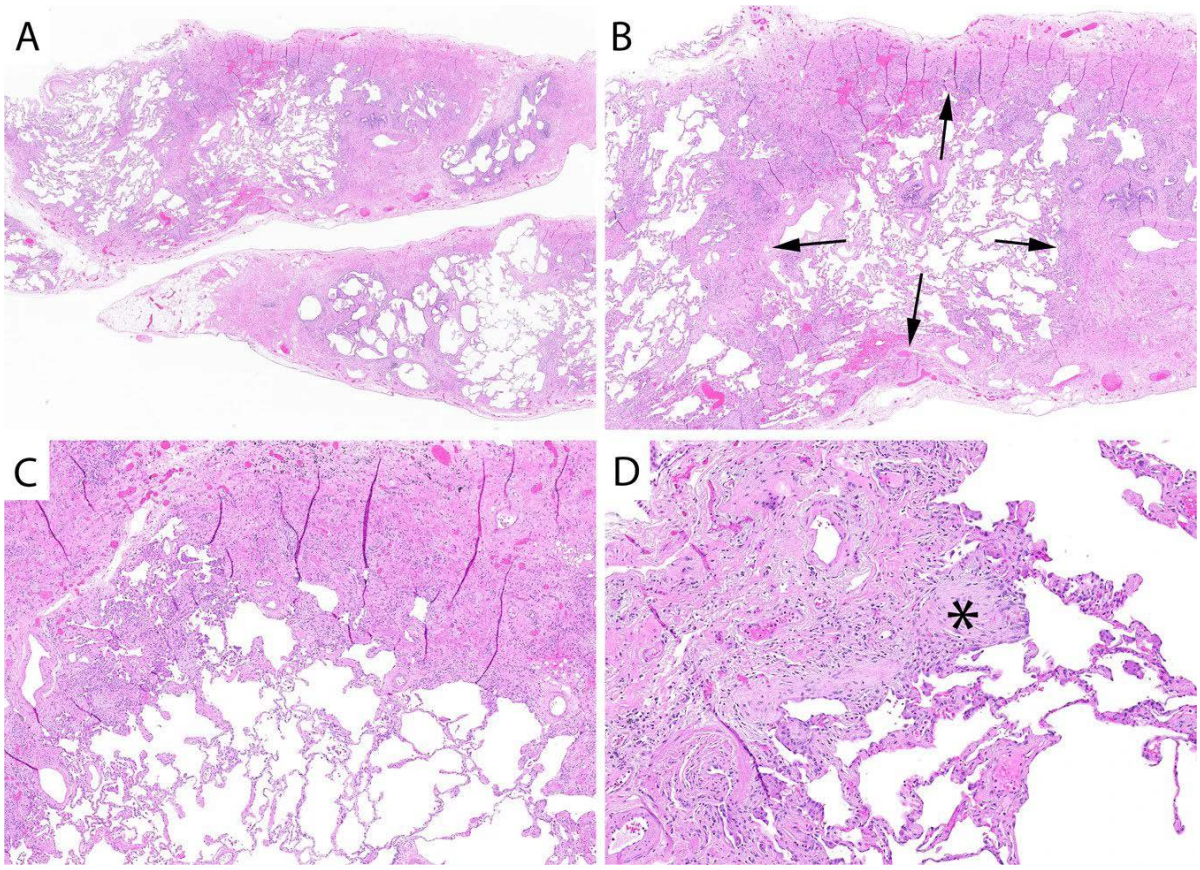

Figure 2. Histologic UIP.

(A) Scanning magnification shows areas of advanced fibrosis with architectural distortion. (B) Fibrosis at the periphery of the lobule (arrows) with sparing of the centrilobular regions. (C) Sharp demarcation between the advanced fibrosis and the normal appearing alveolar walls. (D) Evidence of active injury in the form of fibroblast foci (asterisk).

UIP, usual interstitial pneumonia.

Reprinted from Smith ML. The histologic diagnosis of usual interstitial pneumonia of idiopathic pulmonary fibrosis. Where we are and where we need to go. *Mod Pathol*. 2022;35(suppl 1):8-14.

histopathologic changes that primarily affect the subpleural and paraseptal lung parenchyma, fibroblast foci, and the absence of features of any alternative diagnosis.[16,19] Similar to the radiological diagnostic criteria, a diagnosis of "probable UIP" can be made when some of the above characteristics are present, but not all, still with no indication of an alternative diagnosis (Table 2).[16] If certain histopathologic features that suggest a non-UIP diagnosis are present, patients should be categorized as having an alternative diagnosis. Thus, it is important for pathologists to search for such features including acute lung injury, lymphoid hyperplasia, organizing pneumonia, pleuritis, and other features suggesting a connective tissue disease–related ILD or those suggesting fibrotic hypersensitivity pneumonitis, such as airway centricity or granulomas, as these are the more common differential diagnoses for IPF.[25]

The panelists discussed the challenges of identifying secondary diagnoses in patients with complicated histologic profiles. "You can have lung disease be your first and predominant manifestation of a rheumatologic disease. It is important to make the diagnosis so you're not behind the eight ball in terms of management," said Ann Chauffe, DO, MPH, an associate professor of medicine at the University of Florida College of Medicine, in Gainesville, Florida. Dr Chauffe stated that she often diagnoses patients with IPF, and will observe how their disease changes over time. "Sometimes whether there is an underlying autoimmune diagnosis is unclear. For example, the idiopathic pneumonia with autoimmune features or 'IPAF' group: Typically, we treat these patients, but it is a more challenging scenario that highlights the need for a rheumatologist on the care team," Dr Chauffe said. Careful patient assessment and a thorough history can provide valuable insight into a patient's clinical profile and exclude secondary causes, the panelists explained. "Patients may not know to tell you everything to which they've been exposed. Sometimes, it is those factors that they don't even know that they have been exposed to that can lead to disease," Dr Hariri said. Dr Teague noted that he works with occupational medicine clinicians who are excellent at taking detailed histories, especially related to occupational and environmental exposures, and finds it helpful to collaborate with them to inform diagnostic decisions.

Serological Testing

The 2018 guideline recommended routine serological testing to exclude connective tissue diseases as an underlying cause of ILD.[19] The panelists agreed that serological testing is important for informing diagnoses, and often will order a large amount of tests regardless of hospital size and setting. "For the serologic markers, there's an entire panel," Dr Teague said. "Obviously, we at National Jewish Health as a tertiary/quaternary referral center are biased because by the time patients get to us, they are struggling for a diagnosis. So, our clinicians tend to order extensive serologic testing to aid in finding an underlying cause of the lung fibrosis that can be treated." Dr Chauffe

Table 2. IPF Diagnosis on the Basis of HRCT and Biopsy Patterns, Developed Using Consensus By Discussion

IPF suspected[a]		Histopathology pattern[b]			
		UIP	Probable UIP	Indeterminate for UIP or biopsy not performed	Alternative diagnosis
HRCT pattern	UIP	IPF	IPF	IPF	Non-IPF diagnosis
	Probable UIP	IPF	IPF	IPF (likely)[c]	Non-IPF diagnosis
	Indeterminate	IPF	IPF (likely)[c]	Indeterminate[d]	Non-IPF diagnosis
	Alternative diagnosis	IPF (likely)[c]	Indeterminate[d]	Non-IPF diagnosis	Non-IPF diagnosis

CT, computed tomography; **HRCT,** high-resolution computed tomography; **IPF,** idiopathic pulmonary fibrosis; **UIP,** usual interstitial pneumonia.

[a] "Clinically suspected of having IPF" is defined as unexplained patterns of bilateral pulmonary fibrosis on chest radiography or chest CT, bibasilar inspiratory crackles, and age >60 years. Middle-aged adults (>40 and <60 years old) can rarely present with otherwise similar clinical features, especially in patients with features suggesting familial pulmonary fibrosis.

[b] Diagnostic confidence may need to be downgraded if histopathologic assessment is based on transbronchial lung cryobiopsy, given the smaller biopsy size and greater potential for sampling error compared with surgical lung biopsy.

[c] IPF is the likely diagnosis when any of the following features are present: 1) moderate to severe traction bronchiectasis and/or bronchiolectasis (defined as mild traction bronchiectasis and/or bronchiolectasis in 4 or more lobes, including the lingula as a lobe, or moderate to severe traction bronchiectasis in 2 or more lobes) in a man >50 years of age or in a woman >60 years of age, 2) extensive (>30%) reticulation on HRCT and age >70 years of age, 3) increased neutrophils and/or absence of lymphocytosis in bronchoalveolar lavage fluid, and 4) multidisciplinary discussion produces a confident diagnosis of IPF.

[d] Indeterminate for IPF 1) without an adequate biopsy remains indeterminate and 2) with an adequate biopsy may be reclassified to a more specific diagnosis after multidisciplinary discussion and/or additional consultation.

Adapted from Raghu G, Remy-Jardin M, Myers JL, et al. Diagnosis of idiopathic pulmonary fibrosis. An official ATS/ERS/JRS/ALAT clinical practice guideline. *Am J Respir Crit Care Med*. 2018;198(5):e44-e68.

Reprinted with permission of the American Thoracic Society. Copyright © 2023 American Thoracic Society. All rights reserved.

Raghu G, Remy-Jardin M, Richeldi L, et al. Idiopathic pulmonary fibrosis (an update) and progressive pulmonary fibrosis in adults: an official ATS/ERS/JRS/ALAT clinical practice guideline. *Am J Respir Crit Care Med*. 2022;205(9):e18-e47.

The *American Journal of Respiratory and Critical Care Medicine* is an official journal of the American Thoracic Society.

agreed: "The recommendations are to check ANA [antinuclear antibody], myositis panel, rheumatoid factor, and CCP [cyclic citrullinated peptide], as these are commonly associated with lung disease." Dr Kopas stated that in her practice, "excluding other causes is the main focus at the beginning. We are still on the hunt for something that can be well managed." Dr Chauffe noted that if physicians do not have a direct relationship with a rheumatologist at their own center, "many of the tertiary centers do have rheumatologists that will work with pulmonologists and other specialists. Although it may take a bit of effort, it is important to find somebody with whom to collaborate. The landscape has dramatically changed, and more private practice rheumatologists are expecting to co-manage with pulmonologists."

Genomic Classifier

A new genomic classifier has been developed and validated for lung tissue from transbronchial forceps biopsy for the diagnosis of UIP.[26] Reports of the sensitivity and specificity of the classifier range from 59% to 80% and 78% to 100%, respectively.[16,26-29] For UIP identification among patients with ILDs of unknown type, the sensitivity and specificity are 68% and 92%, respectively.[16] The 2022 guideline update made no recommendation for or against genomic classifier testing because the committee could not reach a consensus on the topic.[16] The panelists generally consider the genomic classifier as part of the diagnostic puzzle and are still learning how best to use the information it provides.

Surgical Lung Biopsy Considerations

The panelists discussed the changing role of biopsy as the use of diagnostic imaging increases. Dr Hariri said, "We've seen a huge shift in the last decade where previously many more patients were undergoing surgical lung biopsy. Ideally, these would not be patients who are in an acute exacerbation or accelerated phase of their disease. Because of the number of patients undergoing biopsy, we would frequently see the spectrum of disease, including very classical cases of UIP and hypersensitivity pneumonitis. In these last 5 years, we have seen a shift towards obtaining biopsy only in the more atypical cases that fall into the HRCT indeterminate or alternative diagnosis category." Dr Hariri explained that pathologists have had to shift their abilities to diagnose more complicated cases as well as provide additional insight into potential etiologies. "The reason we have undergone this transformation towards also aiding in identifying etiology on pathology is because of the changes and differences in therapy for IPF and other non-IPF, PPF ILDs," she said.

Cryobiopsy

In the updated 2022 guideline, transbronchial lung cryobiopsy is regarded as an acceptable alternative to surgical lung biopsy in medical centers with experience performing the procedure and interpreting test results.[16] "You start with a cold probe and place it into tissue. The tissue is frozen and you remove the probe quickly, and there you have your biopsy," said Dr Kopas, who has been performing cryobiopsies for 7 years. Dr Hariri emphasized the importance of referring to a specialist with experience in cryobiopsy collection. "Not all pulmonologists have experience in performing cryobiopsy. Experience matters to improve the likelihood that a cryobiopsy specimen will have diagnostic utility."

Dr Kopas explained that the architecture of a cryobiopsy sample has certain benefits, as it does not get crushed as easily as samples might be with forceps and the sample is larger. Dr Hariri noted important safety considerations for cryobiopsy, including how experienced the center is at sample collection and the location of the sample that needs to be collected. Dr Kopas agreed that the procedure has "a bit of a learning curve," and maintains protocols in the operating room describing the equipment she needs as well as the roles of the technician and nurse. "It is not so much that cryobiopsy is a particularly difficult procedure to perform. The expertise is necessary in how do you handle respiratory failure during the procedure. How do you handle bleeds during the procedure, etc? I think that is the trickier part to the procedure," Dr Kopas said.

While Dr Kopas emphasized that transbronchial lung cryobiopsy is not equivalent to surgical lung biopsy, "it is coming to the point where biopsying has become less frequent." Dr Hariri stated that "cryobiopsy provides us with a really useful avenue to be able to examine lung tissue microscopically when surgical lung biopsy is not a viable option; to look for these specific features that might indicate a secondary cause, areas of inflammation that may be targetable by immunosuppression, and also potentially provides tissue for future research in ILD."

Diagnosis of IPF: Guideline Direction In Clinical Practice

If a patient is suspected of having IPF, the ATS/ERS/JRS/ALAT guideline recommends an initial evaluation for identifiable causes of ILD, and if a cause is determined, subsequent evaluation for hypersensitivity pneumonitis, connective tissue disease, pneumoconiosis, or iatrogenic causes, such as radiation exposure or drug toxicity.[16,19] "I rarely have a patient coming in suspected of having IPF. What I have is a patient who has the symptoms of IPF," Dr Kopas said. "In the typical patient, they would present with shortness of breath, dry cough, and/or fatigue. The other example is I have a patient who comes in with an incidental abnormality on a CT scan that could be IPF."

Initial Assessment

Dr Kopas described her initial assessment of a patient with symptoms of IPF. "Once I am with the patient, we conduct an exhaustive history and physical examination where we ask them about all the different exposures, other symptoms, hobbies, occupations, and perform a physical exam. It is very helpful to put a stethoscope to a chest and hear dry crackles, and then not hear wheezing—the absence of other findings is important, too. I then make sure I either already have a quality HRCT scan performed or I am ordering one," Dr Kopas said.

High-Resolution Computed Tomography

For an IPF diagnosis, other known causes of ILD must be excluded, and either an HRCT pattern of UIP or specific combinations of HRCT patterns and histopathology patterns must be present.[19] Dr Teague keeps several key factors in mind when performing HRCT. The first key step is to have the patient at full inspiration when performing imaging. If a patient is not at full inspiration, "you get ground-glass opacity especially in the posterior lower lobes, just due to low lung volumes," he said. Dr Teague noted that it is important to collect a full volumetric scan "so that you can tease out the distribution of abnormality, where it is in the axial plane as well as where it is from top to bottom." Second, Dr Teague emphasized the importance of collecting prone images to rule out atelectasis. "Flip the patient

over and give them a minute or so to re-expand the atelectatic lung, and then you can continue imaging," he explained. Third, Dr Teague collects expiratory scans, examining for air trapping or airway collapse. "If you want to properly assess for airway collapse, you have to perform dynamic expiratory imaging. The patient must actively breathe out while imaging," Dr Teague said, adding that it is important to coach the patient to perform good inspiration and dynamic expiration. Finally, Dr Teague looks for 2 major diagnostic indicators: 1) the "classic UIP pattern of fibrosis," or 2) "other patterns that are more suggestive of an underlying alternative diagnosis that needs to be treated," he said.

The HRCT alternative diagnosis category can be useful for when radiologists recognize a pattern with high confidence, but in cases with a lower confidence radiological pattern, the panelists gravitate more toward indeterminate for UIP HRCT categorization. "If you are going to suggest an alternate diagnosis, how confident do you have to be in just one diagnosis?" Dr Teague explained. "For example, do you have to be fairly certain that it is hypersensitivity pneumonitis? Because we see patients that could have hypersensitivity pneumonitis, but maybe they do not have the 3-density sign or some other features that would make us confident in the diagnosis. There is some debate regarding how confident you must be," he said. "I tend to only use the alternate diagnosis category when I think it is 1, maybe 2 specific diagnoses. I tend to use indeterminate when the pattern just does not fit into the other 3 categories." Patients with the indeterminate phenotype are further evaluated during multidisciplinary discussion (MDD).[16]

The panelists also order pulmonary function tests (PFTs) if they have not already been performed, and work to identify secondary causes. Dr Kopas noted that rheumatologists can be very helpful at this stage. When Dr Chauffe receives a new patient with potential ILD/IPF, she focuses on gathering a thorough history and exam, particularly inquiring about symptoms such as rashes and Raynaud's syndrome, as often these symptoms can be intermittent. Dr Chauffe noted that it can be difficult to characterize patients who are inactive because they may not notice changes in their physical abilities. "I have a very low threshold if people are not doing activities they used to do, or I think I hear anything on the lungs, and I am getting PFTs and an HRCT," Dr Kopas said. She noted that during PFTs it is important to "look for curves that are smooth, which takes a lot of coaching, and catching patients right at the right moment in time, kind of in between coughs." To characterize a patient with potential ILD, spirometry, lung volumes, and diffusing capacity for carbon monoxide (DL_{CO}) all must be evaluated.[17,30]

Multidisciplinary Discussion

Clinical data, HRCT, and pathology, when available, can be considered during MDD for patients without specific diagnoses or potential causes of ILD.[31] MDD is a critical component of the IPF diagnostic process, and was suggested in the 2018 guideline after the 2011 guideline indicated MDD among ILD experts is likely to improve the accuracy of diagnosis.[17,19] The panelists discussed the value and utility of MDD, noting that it can prevent overtreatment, helps with decision making about whether a biopsy is needed, helps to clarify complex clinical cases including those with discordant HRCT and biopsy pathology, and adds confidence to clinical decision making. Dr Kopas said, "I think you get less discordance when you have all of that information and more consensus." Dr Teague agreed that MDD "is key." In the 2022 guideline update, patients with probable UIP are treated more similarly to those with UIP; both UIP and probable UIP can lead to an IPF diagnosis after MDD.[16] "We present a patient and discuss whether they warrant a biopsy that would help in their management. If yes, and the patient was agreeable to undergo biopsy, we reconvene after the biopsy to reevaluate the patient: 'OK, now that we have this additional histologic information, how does that influence what the overall diagnostic picture is for this particular patient?'" Dr Hariri said.

In addition to the decision-making benefits of MDD, the panelists explained how MDD can improve access to care by allowing experts to virtually weigh in on diagnosis and management decisions for patients at rural and community hospitals. "If you want to present a patient, we try to make it pretty easy. We have had a few centers take us up on that offer," Dr Kopas said. "We actually have a set of pulmonologists that are in a completely different part of the city, and they do participate remotely in our multidisciplinary conference," Dr Teague added. At Dr Hariri's center, they have opportunities to present at MDD that are "open to the entire New England area and further for whoever wants to come." Panelists noted that MDD does not always have to be a formal sit-down event. "I am friends with my radiologists; I love working with them," Dr Hariri said. "I just shoot them an email or give them a call to ask if we can look at a patient's information together because, for example, what the CT report says and what I'm seeing on pathology might not quite match up. I want to figure it out together."

In another update, the 2022 guideline states that a patient with an alternative diagnosis on HRCT and probable UIP on histopathology now is considered indeterminate for IPF.[16] "The patients now receiving biopsy are those patients who have 'indeterminate for UIP' or 'alternative diagnosis' on their CT scan, and do not have anything that seems identifiable as a secondary cause. If it is not high-confidence clinical–radiologic hypersensitivity pneumonitis or UIP, for example, we will frequently biopsy those patients," Dr Hariri said. Depending on the country, Dr Hariri noted that bronchoalveolar lavage may be performed prior to or at the time of surgical lung biopsy, and that in Europe, bronchoalveolar lavage is frequently performed prior to lung biopsy. Dr Kopas agreed that in the United States, bronchoalveolar lavage often occurs at the same time as biopsy and said it can be helpful to identify infections or sarcoidosis.

With biopsy, Dr Hariri explained that pathologists are searching for disease patterns, including an assessment of fibrosis, location, destructiveness, and associated features, such as honeycombing, traction bronchiolectasis, airway-centered abnormalities, or inflammation. The overall assessment of all these features informs which UIP category is ultimately selected. "We use the report in order to communicate our level of confidence about the fibrosis pattern and the level of confidence about the underlying etiology—as well as to discuss the relevant features that are present and absent—in order to provide as much information as we possibly can to guide management," Dr Hariri said.

Identifying and Understanding PPF: Guideline-Based Decision Making

Also included in the 2022 guideline update is a consensus definition of PPF. PPF is defined as 2 of 3 criteria (worsening respiratory symptoms, physiologic evidence of

disease progression, or radiological evidence of disease progression) occurring in a patient within the past 12 months and with no alternative explanation.[16] According to the panel, PPF had been discussed within the community by many various names, and "the ATS guideline community essentially decided to use the nomenclature of PPF to indicate that this is a disease that by definition, has progressed, and will most likely continue to cause a reduction in lung function over time," Dr Hariri explained. Dr Kopas suggested that providing a definition for PPF was likely treatment-driven. "I think that we had to come up with a title for it and criteria to go along with that to give credence to this idea of treating it," Dr Kopas said.

PPF is defined separately from IPF; the guideline committee emphasizes that PPF is not a diagnosis, and as such, the definition of PPF is agnostic to the underlying condition causing fibrosis.[16] PPF is "not a diagnosis in itself. It is an umbrella category that covers multiple fibrotic ILDs that progress over time," Dr Hariri said. Of note, patients with a range of autoimmune diseases, including rheumatoid arthritis, systemic sclerosis, mixed connective tissue disease, myositis, Sjögren's syndrome, vasculitis, and systemic lupus erythematosus may all develop PPF secondary to their disease.[16] The panelists stated the importance of monitoring patients with autoimmune diseases for signs of ILD or PPF, and watching patients with ILD for signs and symptoms of systemic autoimmune disease. "The hard part with autoimmune disease is that in many cases, the systemic manifestations can evolve over time," Dr Chauffe said.

Criteria for Disease Progression

The 2022 guideline update lists specific criteria for PPF and how to assess progression via clinical observations, physiologic changes, and radiological assessment (Table 3).[16] "The criteria are essentially about serial assessment of symptoms, PFTs, and radiologic imaging, where patients need to meet criteria that indicate their disease is progressing," Dr Hariri said.

In addition to worsening respiratory symptoms, patients with PPF may have physiologic or radiological evidence of disease progression. Physiologic evidence of disease progression is defined as the presence of either of the following findings, if the findings are attributable to worsening fibrosis: 1) absolute decline in forced vital capacity (FVC) of at least 5% within 1 year of follow-up, and 2) absolute decline in DL_{CO} (corrected for hemoglobin) of greater than 10% within 1 year of follow-up.[16] "A relative decline in FVC of at least 10% has been used in the past,[32] so I think the updated guideline is more on the conservative side. I do think that this is an appropriate place to start," Dr Kopas said. An FVC of at least 5% was chosen by the guideline committee via extrapolation of data from patients with IPF.[16] "It is a tough call. You want to be inclusive, but looking at the other side of the coin, I think there also is a risk of potential overmanagement and overtreatment," Dr Hariri added. Dr Chauffe found it interesting that the 6-minute walk test was not included in the assessment of progression, despite measuring an outcome that she believes is important to patients.

Radiological evidence of disease progression includes visual determination of fibrosis progression, based on the percentage

Table 3. Definition of PPF

In a patient with ILD of known or unknown etiology other than IPF who has radiologic evidence of pulmonary fibrosis, PPF is defined as at least 2 of the following 3 criteria occurring within the past year with no alternative explanation[a]:
1. Worsening respiratory symptoms
2. Physiological evidence of disease progression (either of the following): a. Absolute decline in FVC >5% predicted within 1 year of follow-up b. Absolute decline in DL_{CO} (corrected for Hb) >10% predicted within 1 year of follow-up
3. Radiologic evidence of disease progression (1 or more of the following): a. Increased extent or severity of traction bronchiectasis and bronchiolectasis b. New ground-glass opacity with traction bronchiectasis c. New fine reticulation d. Increased extent or increased coarseness of reticular abnormality e. New or increased honeycombing f. Increased lobar volume loss

CT, computed tomography; **DL_{CO},** diffusing capacity for carbon monoxide; **FVC,** forced vital capacity; **Hb,** hemoglobin; **ILD,** interstitial lung disease; **IPF,** idiopathic pulmonary fibrosis; **PPF,** progressive pulmonary fibrosis.

[a] Although it is critical to exclude alternative explanations of worsening features for all patients with suspected progression, this is particularly important in patients with worsening respiratory symptoms and/or decline in DL_{CO}, given the lower specificity of these features for PPF compared with FVC and chest CT.

Reprinted with permission of the American Thoracic Society. Copyright © 2023 American Thoracic Society. All rights reserved.

Raghu G, Remy-Jardin M, Richeldi L, et al. Idiopathic pulmonary fibrosis (an update) and progressive pulmonary fibrosis in adults: an official ATS/ERS/JRS/ALAT clinical practice guideline. *Am J Respir Crit Care Med.* 2022;205(9):e18-e47.

The *American Journal of Respiratory and Critical Care Medicine* is an official journal of the American Thoracic Society.

of lung volume with fibrosis across the upper, mid, and lower lung zones. The guideline recommends side-by-side comparison of initial and follow-up HRCT images to assess changes.[16]

"I think it is interesting that in discussing HRCT, guideline reviewers did not include any kind of quantitative number for progression," Dr Teague said. "There are definitely artificial intelligence products that are being built. I think it will be interesting to see over the next 5 years if those products get deployed, and if there are specific number criteria for progression that are used. But for now, it is mostly a visual assessment." Dr Teague expressed concern that subtle changes might be missed due to the lack of quantitation. The guideline lists notable features to look for in those with suspected PPF, including increased traction bronchiectasis and bronchiolectasis; new ground-glass opacity with traction bronchiectasis; new fine reticulation; increased coarseness of reticular abnormality; new or increased honeycombing; and increased lobar volume loss.[16]

Radiological findings can differ between progression in IPF and in ILDs other than IPF. According to research highlighted in the guideline update, progression in IPF often appears as an exacerbation of existing disease features, such as an increase in the extent of UIP, a growing size and number of honeycomb cysts, and/or progression of traction bronchiectasis and bronchiolectasis.[16,33-36] Outside of IPF, radiological findings may be more variable and may include progressive changes from ground glass to reticular abnormalities to honeycombing or progression of bronchiectasis and bronchiolectasis.[34] "As a pathologist, I am really fascinated with the pathobiology and the pathophysiology of these diseases, especially since many studies have shown heterogeneity in rates and frequency of progression, even amongst patients with IPF," Dr Hariri said. "Although the end stage for these PPF cases ultimately will be UIP, that doesn't necessarily mean that their trajectory in terms of disease pathogenesis is the same patient to patient."

Early Detection and Screening

The panelists also discussed the importance of early detection of progression and the potential for identification of patients who are at high risk for progression. Dr Kopas thought identifying a patient as high risk would not change the management of their condition, but would influence how often the patient was monitored for progression. Dr Chauffe noted that screening is important for patients with diseases at risk for ILD development. "We have recommendations for diffuse systemic sclerosis, primarily, and scleroderma in general, where we recommend baseline HRCTs, PFTs, and echocardiography.[37] Then, generally speaking, every 6 months or so, you should be repeating PFTs. If there is any change clinically, repeat the HRCTs and echocardiography at least annually—at least for the first 5 years from non-Raynaud's phenomenon as a symptom for those patients. Overall, the recommendations are well laid out if clinicians are paying attention to them," Dr Chauffe said.

Dr Teague expects that an increase in lung cancer screening exams will increase the number of patients with ILDs identified, and considers increasing lung cancer screenings a priority. "We know ILD patients have a much higher prevalence of lung cancer. We know lung cancer patients tend to have a higher prevalence of ILD than the general population. It makes sense to improve uptake of screening for both purposes—for early detection for both purposes—which could be a real win for everyone in the pulmonary field to impact outcomes in both diseases for these patients," Dr Hariri said.

Clinical Implications of an Umbrella Diagnosis

The 2022 guideline update lists selected patterns that can manifest as PPF and provide guidance for characterization and management. Many different fibrotic lung diseases can manifest PPF.[16] The panelists discussed the implications of grouping such conditions together under the PPF umbrella. On the one hand, because these diseases are less common, Dr Kopas believes it is beneficial to group them together for statistical analyses, and Dr Chauffe thought this made sense for analyzing treatment outcomes, especially if subgroup analyses could further characterize individual diseases. On the other hand, Dr Chauffe said treatment could differ for each individual condition, and if you are trying to catch disease before it reaches a certain end point, "when you delve into what little data there is, it is more complex; and you really do have to split if you are going to treat appropriately."

Dr Hariri described 2 patients who both ultimately reach a diagnosis of UIP/IPF, but who progress through very different disease trajectories at different rates. "What is the difference between these patients? Are various management strategies going to be more or less efficacious in each of these individuals? What about when there are more than a few management strategies available for PPF with different mechanisms of action? How will we decide which strategy is best for which patient? To put it another way, do we need to move towards patient-specific, precision medicine–based management platforms? I am worried that if we lump everyone together, we'll never get the answer to these questions," she said. Dr Chauffe also said it is important to accept that these patients most likely will require treatments that target multiple pathways of disease.

Gastroesophageal Reflux Disease and ILD

The 2022 guideline update also includes a discussion of gastroesophageal reflux disease (GERD) in which the guideline committee does not support using reflux medications or antireflux surgery to treat respiratory symptoms in patients with IPF.[16] The committee recognizes that reflux medication or antireflux surgery may be appropriate for some patients with IPF for improving GERD symptoms.[16] The panelists discussed the prevalence of GERD among their patients and the utility of treating it. "I think GERD is underrecognized and underdiagnosed," Dr Teague said. Dr Kopas explained, "There are many side effects to GERD treatments, and if you've ever had a patient who has had a fundoplication, there are some negative implications to that surgery as well. Yes, you should screen in an appropriate way for acid reflux–related disease, and if they have it, treat it; and if they do not, do not." She noted that patients with ILD may experience a cough that could be helped by treating GERD or allergies, because there are no effective treatment options for cough alone for patients with ILDs.

The panelists agreed that screening for GERD is symptom-dependent. Dr Kopas noted not all GI clinicians screen or do proper assessment for GERD. "If they are not doing manometry, a pH probe, or Bravo pH test, then GERD can be missed or, conversely, overtreated," Dr Kopas said.

Drs Hariri and Teague also explained that reflux and aspiration can affect how the lungs appear on imaging and pathology, and may create the appearance of alternate features. "It is not uncommon for us to see aspiration-related changes with some scarring and some bronchiectasis that gets labeled ILD," Dr Teague said. The panelists agreed that increasing

awareness about this current condition would help prevent this confusion. Dr Teague added, "Working out those 2 patterns is definitely helpful to the pulmonologist and rest of the care team involved in trying to treat the patient as a whole."

Other Clinical Guidelines

Multiple clinical guidelines exist for physicians treating patients with ILDs. "There are a lot of documents available to help guide how to manage these patients in the best way possible," Dr Hariri said. The panelists briefly discussed the benefits and challenges to having a wide range of clinical guidance resources. "I think that when you take the connective tissue disorder, hypersensitivity pneumonitis, and IPF documents, they all try to stay somewhat in the same lane. As long as there is consistency, I'm happy with that," Dr Kopas said.

Forward Perspective on ILD/PPF Guidelines

Lastly, the panelists discussed changes they expect to see in the future in regard to the diagnosis and management of IPF and PPF. In rheumatology, Dr Chauffe said there is a lack of good recommendations for therapy or management of patients with ILDs. "I think that is an area for great opportunity. Where the next 5 years lies hopefully is having more targeted approaches to underlying diseases and diagnosing them earlier," Dr Chauffe said. Dr Kopas would like to see more guidance on cryobiopsy: "We need more numbers on that—how many biopsies, which parts of the lung should you do, and how, and when, and why." She also would like to see more data on genomics and clinical applications of genomic data, as well as how to treat the individual subcategories within the PPF umbrella.

Dr Hariri agreed and expressed the need for accurate biomarkers to predict disease progression. She also would like to see early detection and screening prioritized. "One of the big keys to that is the ability to identify patients before significant lung remodeling has occurred, in order to have a possibility of preventing further damage from occurring and further lung function decline," she said. Dr Teague is looking forward to advancements in scanner technology that will continue to improve spatial resolution and lower radiation doses while increasing user-friendliness and accessibility.

Conclusion

Clinical guidelines have undergone important updates that will affect how patients with ILD are diagnosed.[16] In this roundtable discussion, ILD expert panelists placed these updates into context and provided valuable clinical insight into what these updates look like in practice. ILD is a varied and often complex condition that demands evaluation and management from experts and specialists.[17,19] According to the panel, careful imaging, thoughtful conversations with patients, and effective leveraging of MDD are key to thorough characterization of patients with ILDs. The panelists identified areas with remaining unmet needs and underscored the importance of screening and early detection. As technology improves and new data are collected, the identification and management of patients with ILDs will continue to evolve to support earlier diagnosis, improved care, and optimal outcomes.

References

1. Mikolasch TA, Porter JC. Transbronchial cryobiopsy in the diagnosis of interstitial lung disease: a cool new approach. *Respirology*. 2014; 19(5):623-624.
2. Coelho AC, Knorst MM, Gazzana MB, et al. Predictors of physical and mental health-related quality of life in patients with interstitial lung disease: a multifactorial analysis. *J Bras Pneumol*. 2010;36(5):562-570.
3. Kreuter M, Bendstrup E, Russell AM, et al. Palliative care in interstitial lung disease: living well. *Lancet Respir Med*. 2017;5(12):968-980.
4. Hewlett JC, Kropski JA, Blackwell TS. Idiopathic pulmonary fibrosis: epithelial-mesenchymal interactions and emerging therapeutic targets. *Matrix Biol*. 2018;71-72:112-127.
5. Maher TM, Bendstrup E, Dron L, et al. Global incidence and prevalence of idiopathic pulmonary fibrosis. *Respir Res*. 2021;22(1):197.
6. Coultas DB, Zumwalt RE, Black WC, et al. The epidemiology of interstitial lung diseases. *Am J Respir Crit Care Med*. 1994;150(4):967-972.
7. Swigris JJ, Kuschner WG, Jacobs SS, et al. Health-related quality of life in patients with idiopathic pulmonary fibrosis: a systematic review. *Thorax*. 2005;60(7):588-594.
8. Fujimoto H, Kobayashi T, Azuma A. Idiopathic pulmonary fibrosis: treatment and prognosis. *Clin Med Insights Circ Respir Pulm Med*. 2016;9(suppl 1):179-185.
9. King TE Jr, Pardo A, Selman M. Idiopathic pulmonary fibrosis. *Lancet*. 2011;378(9807):1949-1961.
10. Zheng Q, Cox IA, Campbell JA, et al. Mortality and survival in idiopathic pulmonary fibrosis: a systematic review and meta-analysis. *ERJ Open Res*. 2022;8(1):00591-2021.
11. Zaman T, Lee JS. Risk factors for the development of idiopathic pulmonary fibrosis: a review. *Curr Pulmonol Rep*. 2018;7(4):118-125.
12. Richeldi L. Idiopathic pulmonary fibrosis: current challenges and future perspectives. *Eur Respir Rev*. 2013;22(128):103-105.
13. King TE Jr. Clinical advances in the diagnosis and therapy of the interstitial lung diseases. *Am J Respir Crit Care Med*. 2005;172(3):268-279.
14. Tzilas V, Tzouvelekis A, Chrysikos S, et al. Diagnosis of idiopathic pulmonary fibrosis "pragmatic challenges in clinical practice." *Front Med* (Lausanne). 2017;4:151.
15. Lamas DJ, Kawut SM, Bagiella E, et al. Delayed access and survival in idiopathic pulmonary fibrosis: a cohort study. *Am J Respir Crit Care Med*. 2011;184(7):842-847.
16. Raghu G, Remy-Jardin M, Richeldi L, et al. Idiopathic pulmonary fibrosis (an update) and progressive pulmonary fibrosis in adults: an official ATS/ERS/JRS/ALAT clinical practice guideline. *Am J Respir Crit Care Med*. 2022;205(9):e18-e47.
17. Raghu G, Collard HR, Egan JJ, et al. An official ATS/ERS/JRS/ALAT statement: idiopathic pulmonary fibrosis: evidence-based guidelines for diagnosis and management. *Am J Respir Crit Care Med.* 2011;183(6):788-824.
18. Raghu G, Rochwerg B, Zhang Y, et al. An official ATS/ERS/JRS/ALAT clinical practice guideline: treatment of idiopathic pulmonary fibrosis. An update of the 2011 clinical practice guideline. *Am J Respir Crit Care Med*. 2015;192(2):e3-e19.
19. Raghu G, Remy-Jardin M, Myers JL, et al. Diagnosis of idiopathic pulmonary fibrosis. An official ATS/ERS/JRS/ALAT clinical practice guideline. *Am J Respir Crit Care Med*. 2018;198(5):e44-e68.
20. Hochhegger B, Marchiori E, Zanon M, et al. Imaging in idiopathic pulmonary fibrosis: diagnosis and mimics. *Clinics* (Sao Paulo). 2019;74:e225.
21. Hunninghake GW, Lynch DA, Galvin JR, et al. Radiologic findings are strongly associated with a pathologic diagnosis of usual interstitial pneumonia. *Chest*. 2003;124(4):1215-1223.
22. Lynch DA, Godwin JD, Safrin S, et al; Idiopathic Pulmonary Fibrosis Study Group. High-resolution computed tomography in idiopathic pulmonary fibrosis: diagnosis and prognosis. *Am J Respir Crit Care Med*. 2005;172(4):488-493.
23. Yagihashi K, Huckleberry J, Colby TV, et al. Radiologic-pathologic discordance in biopsy-proven usual interstitial pneumonia. *Eur Respir J*. 2016;47(4):1189-1197.
24. Brownell R, Moua T, Henry TS, et al. The use of pretest probability increases the value of high-resolution CT in diagnosing usual interstitial pneumonia. *Thorax*. 2017;72(5):424-429.
25. Smith ML. The histologic diagnosis of usual interstitial pneumonia of idiopathic pulmonary fibrosis. Where we are and where we need to go. *Mod Pathol*. 2022;35(suppl 1):8-14.

Mailing label placed here

26. Raghu G, Flaherty KR, Lederer DJ, et al. Use of a molecular classifier to identify usual interstitial pneumonia in conventional transbronchial lung biopsy samples: a prospective validation study. *Lancet Respir Med*. 2019;7(6):487-496.
27. Kheir F, Alkhatib A, Berry GJ, et al. Using bronchoscopic lung cryobiopsy and a genomic classifier in the multidisciplinary diagnosis of diffuse interstitial lung diseases. *Chest*. 2020;158(5):2015-2025.
28. Pankratz DG, Choi Y, Imtiaz U, et al. Usual interstitial pneumonia can be detected in transbronchial biopsies using machine learning. *Ann Am Thorac Soc*. 2017;14(11):1646-1654.
29. Richeldi L, Scholand MB, Lynch DA, et al. Utility of a molecular classifier as a complement to high-resolution computed tomography to identify usual interstitial pneumonia. *Am J Respir Crit Care Med*. 2021;203(2):211-220.
30. Zibrak JD, Price D. Interstitial lung disease: raising the index of suspicion in primary care. *NPJ Prim Care Respir Med*. 2014;24:14054.
31. Teoh AKY, Holland AE, Morisset J, et al; ILD MDM Delphi Collaborators. Essential features of an interstitial lung disease multidisciplinary meeting: an International Delphi Survey. *Ann Am Thorac Soc*. 2022;19(1):66-73.
32. Maher TM, Brown KK, Kreuter M, et al; INBUILD trial investigators. Effects of nintedanib by inclusion criteria for progression of interstitial lung disease. *Eur Respir J*. 2022;59(2):2004587.
33. Akira M, Inoue Y, Arai T, et al. Long-term follow-up high-resolution CT findings in non-specific interstitial pneumonia. *Thorax*. 2011;66(1):61-65.
34. Lee HY, Lee KS, Jeong YJ, et al. High-resolution CT findings in fibrotic idiopathic interstitial pneumonias with little honeycombing: serial changes and prognostic implications. *AJR Am J Roentgenol*. 2012;199(5):982-989.
35. Yamauchi H, Bando M, Baba T, et al. Clinical course and changes in high-resolution computed tomography findings in patients with idiopathic pulmonary fibrosis without honeycombing. *PLoS One*. 2016;11(11):e0166168.
36. Jacob J, Aksman L, Mogulkoc N, et al. Serial CT analysis in idiopathic pulmonary fibrosis: comparison of visual features that determine patient outcome. *Thorax*. 2020;75(8):648-654.
37. Hoffmann-Vold A-M, Maher TM, Philpot EE, et al. The identification and management of interstitial lung disease in systemic sclerosis: evidence-based European consensus statements. *Lancet Rheumatol*. 2020;2(2):e71–e83.

Disclosures: Dr Hariri reported that she is a consultant to Bioclinica, Boehringer Ingelheim, and Pliant Therapeutics, and has received grant/research support from Boehringer Ingelheim. Dr Chauffe reported that she is a consultant to and has received speaking fees from Boehringer Ingelheim, and has received grant/research support from Argenx, Novartis, Priovant Therapeutics, UCB, and Vera Therapeutics. Dr Kopas reported that she has received speaking fees from Boehringer Ingelheim, and has received grant/research support from Gala Therapeutics, Nuvara Therapeutics, Pulmonx, and Sanofi. Dr Teague reported that he has received speaking fees from Boehringer Ingelheim.

All faculty received compensation from Boehringer Ingelheim for their participation.

Disclaimer: This monograph is designed to be a summary of information. While it is detailed, it is not an exhaustive clinical review. McMahon Publishing, Boehringer Ingelheim, and the authors neither affirm nor deny the accuracy of the information contained herein. No liability will be assumed for the use of this monograph, and the absence of typographical errors is not guaranteed. Readers are strongly urged to consult any relevant primary literature.

Copyright © 2023 McMahon Publishing, 545 West 45th Street, New York, NY 10036. Printed in the USA. All rights reserved, including the right of reproduction, in whole or in part, in any form.

SR2215 MARCH 2023

PC-US-128955